



***FA-C Mutasyon Olan Çocuk Hastada Şiddetli Kulak Anomalisi ve Erken
Başlangıçlı Kemik İliği Yetmezliği: Olgu Sunumu***

***FA-C Mutation in Children with Severe Ear Anomalies and The Early Onset
of Bone Marrow Failure: Case Report***

Zeynep Canan Özdemir, Ayşe Bozkurt Turhan, Özcan Bör, Cansu Sivrikaya

Eskişehir Osmangazi Üniversitesi Tıp Fakültesi, Çocuk Hematoloji/onkoloji Bilim Dalı, Eskişehir

ÖZ

33 aylık kız hasta solukluk ve halsizlik şikayeti ile başvurdu. Fizik muayenede mikrosefali, auricula displazisi, büyüme geriliği, dismorfik görünümü, iskelet anomalileri vardı. Laboratuvar incelemesinde trombositopeni ve anemi saptandı. Mitomisinle uyarılmış kromozom kırılma testinde kromozomal instabilite gösterildi. Gen sekans analizi ile FA-C mutasyonu belirlendi. Klinik ve laboratuvar bulgular ile Fankoni anemisi tanısı konuldu FA-A en yaygın görülen komplementasyon grubudur. FA-C komplementasyon grubu nispeten nadir görülür. Bu makalede nadir görülmesi nedeni ile FA-C mutasyonu olan çocuk hastanın fenotipik özelliklerini bildirmeyi amaçladık.

Anahtar Kelimeler: Fankoni anemisi, FA-C mutasyonu, fenotip

SUMMARY

A thirty-three months old girl presented with palor and fatigue. On clinical examination she had microcephaly, auricular dysplasia, growth retardation, dysmorphic appearance, and skeletal deformities. Laboratory investigation revealed thrombocytopenia and anemia. Mitomycin induced chromosome breakage was detected showing chromosomal instability. FA-C mutation was identified by gene sequencing analysis. Fanconi anemia (FA) was diagnosed with clinical and laboratory findings. FA-A is the most prevalent complementation group. The FA-C complementation group is observed rarely. In this article, we aimed at reporting the phenotypical features of a pediatric patient with FA-C mutation which is relatively rare.

Keywords: Fanconi anemia, FA-C mutation, phenotype

Yayın hakları Güncel Pediatri'ye aittir.

Sorumlu yazar yazışma adresi: Zeynep Canan ÖZDEMİR. Eskişehir Osmangazi Üniversitesi Tıp Fakültesi, Çocuk Sağlığı ve Hastalıkları, Çocuk Hematoloji-Onkoloji BD, Eskişehir, Türkiye

E-posta: oner.ozdemir.md@gmail.com

INTRODUCTION

FA is one of the rare inherited bone marrow failure syndromes with a very high cancer predisposition, including leukemia [1]. Cells derived from FA patients demonstrate chromosomal instability and heightened sensitivity to DNA cross-linking agents, such as mitomycin C, diepoxybutane a feature that is used to make the diagnosis [2] FA patients exhibit extreme clinical and genetical heterogeneity [1]. The clinical manifestations of FA include pre- and post-natal growth retardation; malformations of the kidneys, heart and skeleton (absent or abnormal thumbs and radii, a typical facial appearance with small head, eyes, and mouth, hearing loss, hypogonadism and reduced fertility, cutaneous abnormalities (hyper- or hypopigmentation and cafe-au-lait spots), bone marrow failure and susceptibility to cancer, predominantly acute myeloid leukemia[3,4]. The prevalence of the different complementation groups has been shown to vary considerably according to ethnic origin [5,6]. The frequency of the complementation groups in our country is not known. There are 16 known FA genes, of which FANCA is the most frequent, followed by FANCC and FANCG; FANCB is a rare X-linked recessive gene, while all others are rare autosomal recessive traits [7]. With better understanding of the genetic and molecular basis of the disease, clinical management has improved.

CASE REPORT

A thirty-three months old girl was referred to our clinic due to dysmorphic appearance and bicytopenia from another hospital to which she has presented with the complaint of fatigue and inability to gain weight. Body weight:8500 gr (< 5p), height:80 cm (< 5p), body weight for height: 70-80%, head circumference: 46 cm (<5p). On her physical examination; microphthalmia, hypertelorism, micrognathia, deformities in the teeth, dysplastic bilateral auricula, closed external auditory canal, triangular-shaped face and microcephalic appearance was observed. Bilaterally, hands were in flexion and exhibited deviation towards inside, hypopigmented regions on the abdominal skin were noted with the largest one of 2 x 2 cm size. The complete blood count showed the following: hemoglobin:8,9 gr/dl, MCV:101fl, MCH:32,7 pg, leukocytes:7300/mm³, absolute neutrophil count:3700/mm³, platelets:34.000/ mm³, MPV:8,4 fl, reticulocytes: %3.03, serum iron parameters, vitamin B12, and folate levels were normal. The blood biochemistry was normal and viral markers negative. The bone survey revealed shortness of both forearms, absence of radius, a short ulna and deformation suggesting ulnar flexion, absence of the first metacarpal bones and phalanx in both hands, hypoplasia in the first metatarsus and dysplasia in the tarsal bones in the left foot. The temporal bone tomography detected marked hypoplasia of auricula on both sides, closed bilateral external auditory canals, left middle ear bones of abnormal configuration, large vestibules, and dysplastic lateral semicircular canals. Echocardiography revealed patent ductus arteriosus and bicuspid aortic valve. The abdominal ultrasound investigation results were normal. The bone marrow biopsy performed due

to bicytopenia revealed hypocellularity. Chromosome breakage was detected at a rate of 0.32 using Mitomycin C under the preliminary diagnosis of FA and was considered as chromosomal instability. Among the genetic mutations studies, the FA-C mutation (R548) was detected to be homozygous. The conventional genetic examination reported a chromosomal analysis of 46 XX. HLA screening was performed using material from the parents for the purpose of hematopoietic stem cell transplantation to the patient. The patient, who was found to be compatible with the father, was transferred to a center for stem cell transplantation.

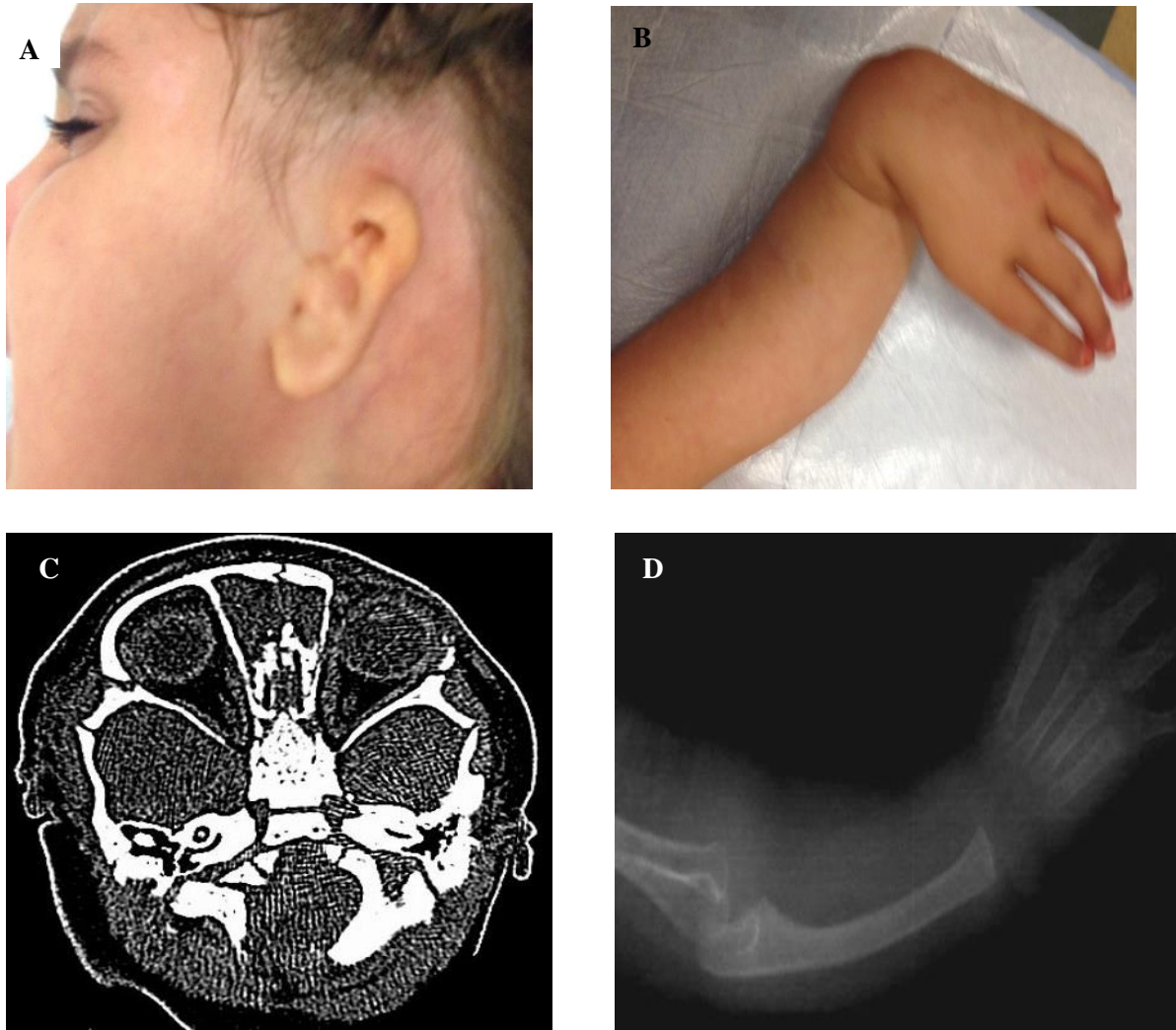


Figure 1. Displastic auricula (A) , absence of thumb, bowing of short ulna , flexion deformity of hands (B), temporal CT shows closed external auditory canal (C) X-rays of upper limbs showing absence of radii and thumb (D).

DISCUSSION

Fanconi anemia is a rare disorder. Clinically, it involves progressive bone failure and a wide range of congenital malformations [8]. The incidence is 1-5/million. The rate of the carriers is presumably between 0.3 and 1% [9]. To date, 15 complementation groups (A, B, C, D1 (BRCA2), D2, E, F, G, I, J (BRIP1), L, M, N (PALB2), O (RAD51C), and P (SLX4)) have been defined [10]. The most recently described is the FAN Q complementation group [7]. The most common is the FA-A complementation group representing approximately two-thirds of the patients in the majority of countries, accounting for 60–66% of FA cases. FA-C and FA-G are less frequent, each accounting for 10–15%, respectively [11].

Clinical signs, age of onset, prognosis of the disease vary depending on the type of mutation. The most common findings include short stature, radial aplasia, skin hyperpigmentation; however, any organ or system may also be affected [3]. Based on a study performed in Hacettepe University, the most common abnormalities respectively include skin pigmentation abnormalities, microphthalmia, growth retardation and microcephaly [12]. Similar results have been reported in the other studies conducted in our country [13,14]. Based on our literature investigation, we failed to detect the phenotypical features of cases with FA-C mutation. Our patient had microcephaly, microphthalmia, dysplastic auricula, marked growth retardation, skeletal abnormalities, dental abnormalities, skin pigmentation abnormalities and cardiac defect. Particularly the skeletal system abnormalities and the ear-associated abnormalities were severe enough to cause a significant loss of function (Figure 1). She had conductive hearing loss and was unable to use her hands. Findings of bone marrow failure had also started. Based on these findings, we believe that the R548 mutation caused severe phenotypical abnormalities in the patient.

The most common FA-C mutation is the IVS4 mutation while the less common ones include 322delG, Q13X in exon 1, R158X in exon 6 and R548X, L554P in exon 14 [8]. In a trial assessing the clinical course of the complementation groups and mutations, FA-C patients with 322delG, IVS4 mutation were reported to have a markedly less growth retardation, less head abnormalities and rarer radial defects and skin abnormalities and urogenital malformations compared to FA-A and FA-G patients [15]. International Fanconi anemia registry has reported that earlier onset of bone marrow failure was associated with poorer survival for complementation group C [16]. Moreover, FA-C patients were reported to have a higher level of central nervous system defects compared to FA-A patients. In FA-C patients, the clinical phenotype was observed to be less intense compared to FA-A and G patients. Comparing these patients among themselves, patients with the 322delG mutation were observed to have less somatic abnormalities, a later onset of aplastic anemia while patients with IVS4 mutation were detected to have an early onset of hematological complications and more somatic abnormalities.

In addition, the patients with IVS-4 mutation in this study were Ashkenazi Jews [15]. Interestingly, no hearing loss was reported in these patients.

Briefly, compared to patients with 322delG mutation and non-C patients, patients with IVS4 and exon 14 mutations (R548X, L554P) are characterized with an intense clinical phenotype, early-onset hematologic findings, multiple congenital abnormalities and a shorter life span [8,17]. In contrast, in a trial comparing Ashkenazi Jews and Japanese patients with IVS4 mutation, the Jewish population was detected to have more major abnormalities and the two ethnical groups showed a similarity for skin pigmentation and thumb and radius abnormalities. Based on these results, different ethnical populations with the same mutation were reported to have a different clinical phenotype [18].

In light of previous reports, phenotypical variations may occur in patients with the same genotype as a result of the effect of various genetic and environmental factors. Therefore, it is important to describe the genotype-phenotype distribution for each country for determining the clinical course and the treatment choice. We believe that determination of the clinical course by establishing the genotypic distribution and creating a large database in Fanconi anemia patients would favorably contribute to follow-up and treatment.

Conflict of interest: The authors declare that they have no conflict of interest.

REFERENCES

1. Morgan NV, Essop F, Demuth I, de Ravel T, Jansen S, Tischkowitz M, et al. A common Fanconi anemia mutation in black populations of sub-Saharan Africa. *Blood* 2005;105:3542–44.
2. Auerbach AD. Fanconi anemia and its diagnosis. *Mut Res* 2009; 668: 4–10.
3. Giampietro PF, Adler-Brecher B, Verlander PC, Pavakis SG, Davis JG, Auerbach AD. The need for more accurate and timely diagnosis in Fanconi anemia: a report from the International Fanconi Anemia Registry. *Pediatrics* 1993;91:1116-20.
4. Joenje H, Patel KJ. The emerging genetic and molecular basis of Fanconi anaemia. *Nat Rev Genet* 2001; 2: 446-457.
5. Joenje H. Fanconi anemia complementation groups in Germany and the Netherlands. *Hum Genet* 1996; 97: 280-82.
6. Savoia A, Zatterale A, Del Principe D, Joenje H. Fanconi anemia in Italy: high prevalence of complementation group A in two geographic clusters. *Hum Genet* 1996; 97: 599-03.
7. Alter BP. Fanconi anemia and the development of leukemia. *Best Pract Res Clin Haematol* 2014; 27: 214-21.

8. Verlander PC, Lin JD, Udono MU, Zhang Q, Gibson RA, Mathew CG, et al. Mutation analysis of the Fanconi anemia gene FACC . Am J Hum Genet 1994; 54:595-01.
9. Verlander PC, Kaporis A, Liu Q, Zhang Q, Seligsohn U, Auerbach AD. Carrier frequency of the IVS4 + 4A→T mutation of the Fanconi anemia gene FAC in the Ashkenazi Jewish population. Blood 1995; 86: 4034–38.
10. Hucl T, Gallmeier E. DNA repair: exploiting the Fanconi anemia pathway as a potential therapeutic target. Pysiol Res 2011; 60:453-65.
11. Kennedy RD, D'Andrea AD. The Fanconi Anemia/BRCA pathway: new faces in the crowd. Genes Dev 2005; 19:2925-40.
12. Altay C, Alikaşifoglu M, Kara A, Tunçbilek E, Ozbek N, Schroeder-Kurth TM. Analysis of 65 Turkish patients with congenital aplastic anemia (Fanconi anemia an dnon-Fanconi anemia): Hacettepe experience. Clin Genet 1997;51:296-02.
13. Yürür Kutlay N, Tuncali T, Ilgin Ruhi H, Karabulut HG, Tukun A. An Evaluation of the Phenotypic Features of Fanconi Anemia Together with DEB/MMC Positivity in 199 Turkish Patients. Turkiye Klinikleri J Med Sci 2013; 33: 1-8.
14. Azık FM, Ileri T, Ince EU, Ertem M, Uysal Z, Gozdasoglu S. Fanconi Anemia: 29 Years Experience in a Single Center. UHOD 2010; 20:201-05.
15. Faivre L, Guardiola P, Lewis C, Dokal I, Ebell W, Zatterale A, et al. Association of complementation group and mutation type with clinical outcome in Fanconi anemia Research Group. Blood 2000; 96:4064-70.
16. Kutler DI, Singh B, Satagopan J, Batish SD, Berwick M, Giampietro PF, et al. A 20-year perspective on the International Fanconi Anemia Registry (IFAR). Blood 2003;101:1249-56.
17. Gillio AP, Verlander PC, Batish SD, Giampietro PF, Auerbach AD. Phenotypic consequences of mutations in the Fanconi anemia FAC gene: an International Fanconi Anemia Registry study. Blood 1997;90:105-10.
18. Futaki M, Yamashita T, Yagasaki H, Toda T, Yabe M, Kato S, et al. The IVS4+4A to T mutation of the Fanconi anemia gene FANCC is not associated with a severe phenotype in Japanese patients. Blood 2000;95:1493-98.